

#SUCCESSIONARY

Challenging surgery for relocation of 1 year old neglected dislocated total hip prosthesis

Department of Orthopaedics

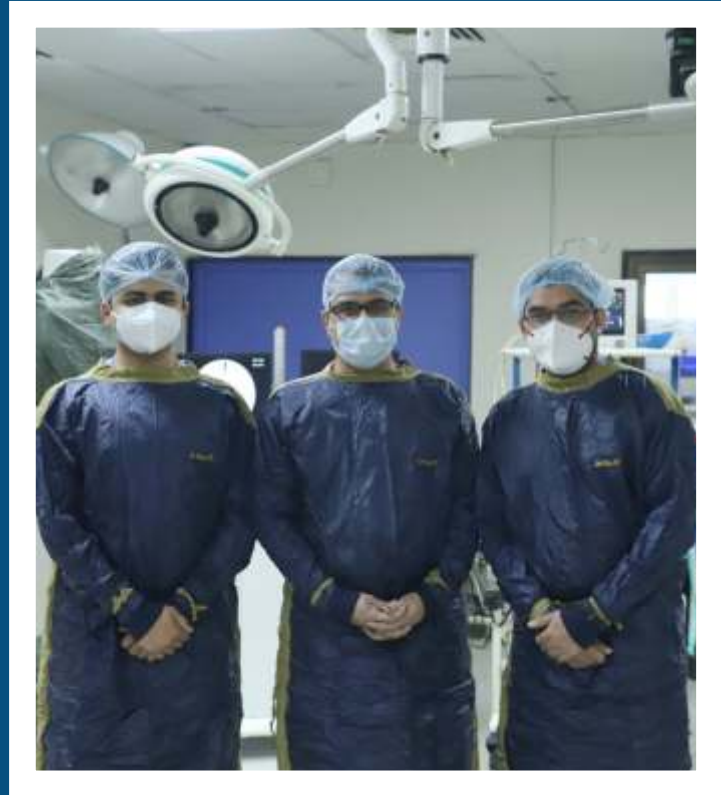
A 42 year old male patient from Madhya Pradesh with severe ankylosing spondylitis visited the Department of Orthopaedics at Parul Sevashram Hospital with 1 year old neglected dislocated right total hip replacement.

The patient was operated for open reduction of the prosthetic hip joint along with extensive soft tissue release around the hip joint along with debridement of the metallosis.

The Patient was happy to walk with full weight bearing after the surgery; before getting discharged from the hospital.

Team of Experts at Parul Sevashram Hospital ensure optimal outcome in such complex and challenging cases with high risk of nerve injury.

Parul[®] Sevashram Hospital



Operating Surgeon :

Dr. Karthik Vishwanathan,
Dr. Ketas Mahajan, Dr. Nachiketa Parikh

Anaesthetist : Dr. Hetal Parikh,

Dr. Nirali Prajapati