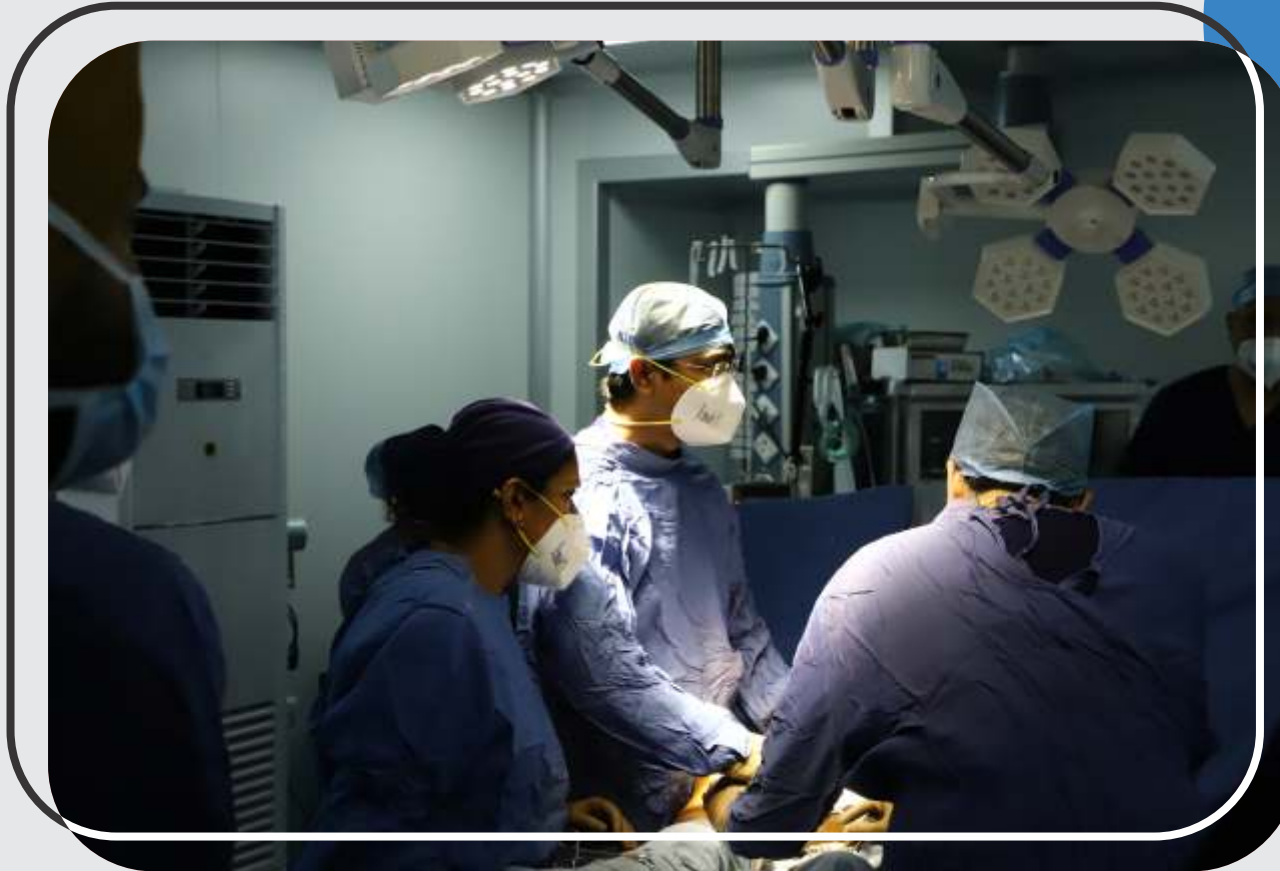


Department of Obstetrics & Gynecology



Laprosopic Neovaginoplasty succesfully performed at Parul Sevashram Hospital for a 23 years old female having Primary Amenorrhea