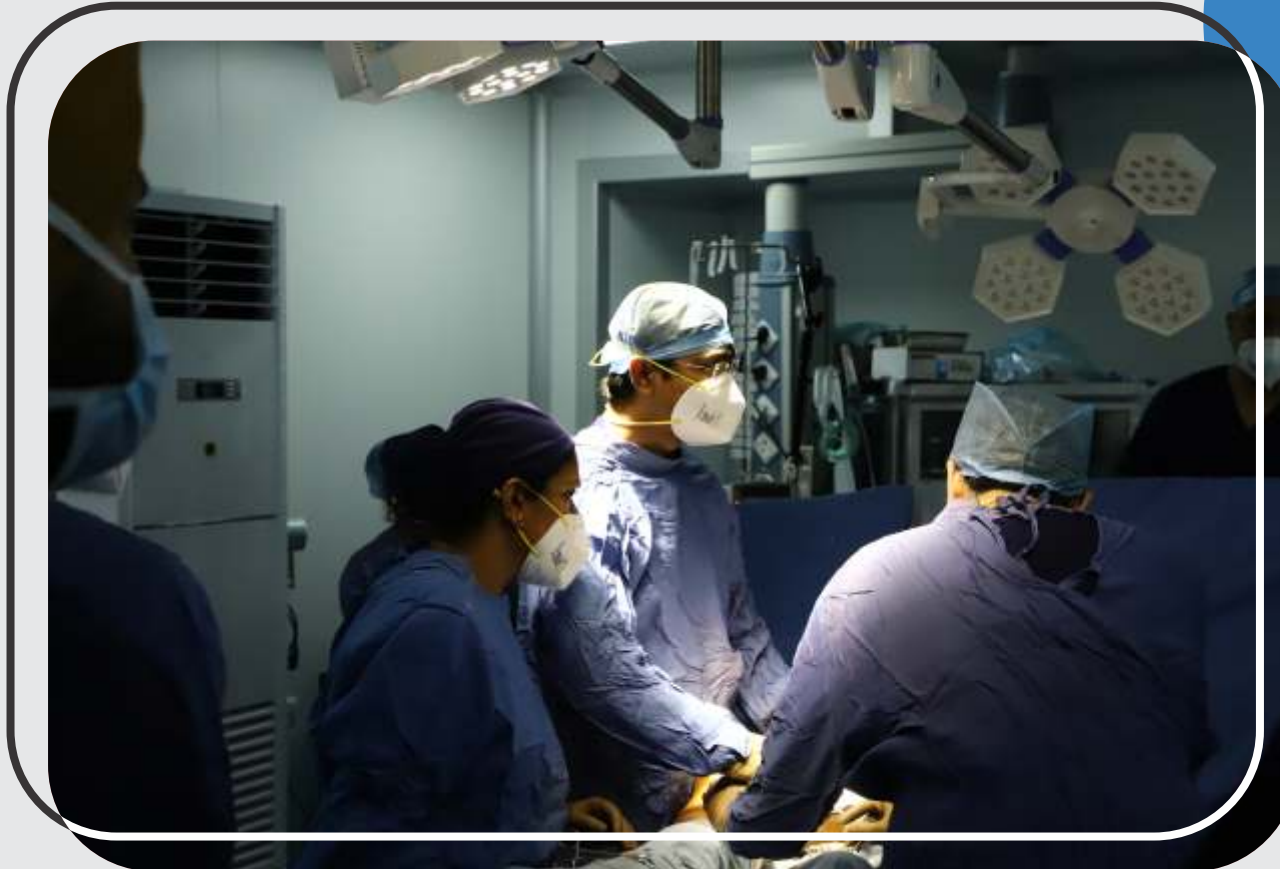

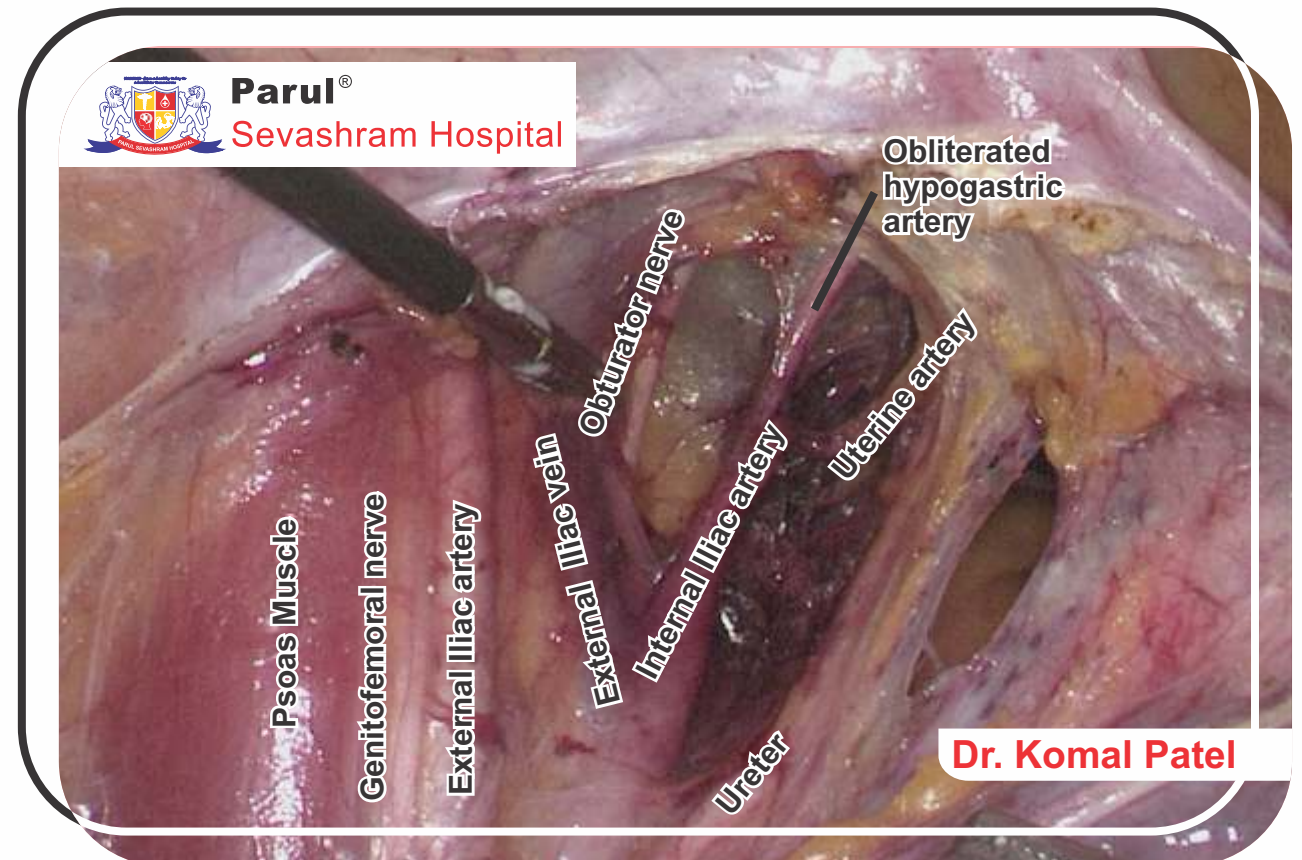
Department of Gynecology



Successful treatment of 51 years old female for Laparoscopic pelvic Lymphadenectomy with hysterectomy in endometrial carcinoma.



**Minimal
Invasive Surgery
- Clinical Retro
peritoneal
Anatomy on
Laparoscopy**



#SUCCESSTORY

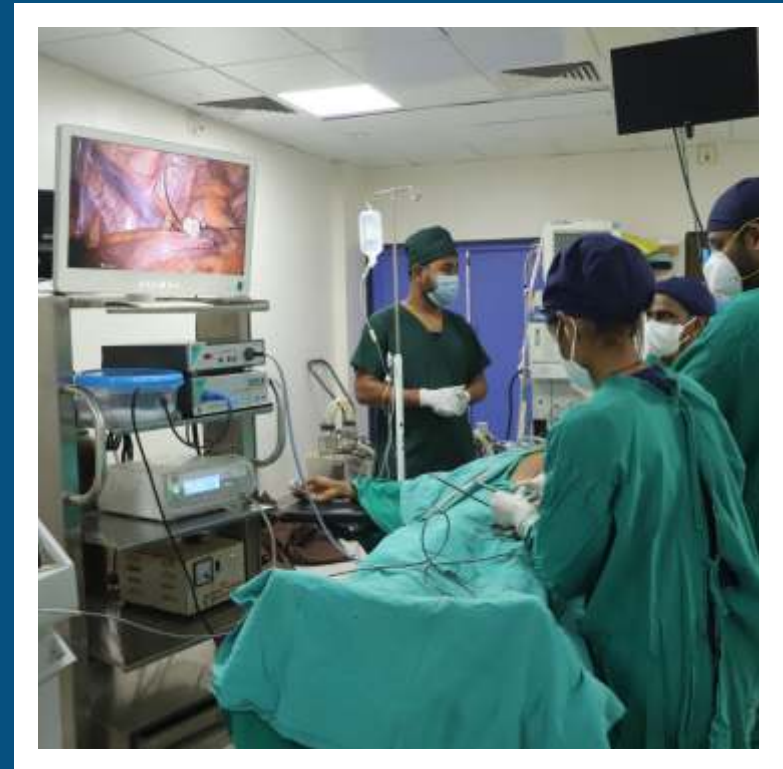Laposcopic Removal of Myometrial Cyst

Department of Obstetrics & Gynecology

A 39 year old female with complaints of abdominal pain presented at Obstetrics & Gynecology Department of Parul Sevashram Hospital. Patient was diagnosed with Benign Ovarian Cystadenoma (20*15*10 cm) with normalCA125.

Having the history of three previous unsuccessful surgeries for the same complaint; patient was operated through minimal invasive route at Parul Sevashram Hospital. Surgeons separated the Uterus laterally by dissection of large cystic mass thereby preserving the uterus by Laparoscopic surgery. The biopsy was suggestive of Myometrial Cyst.

Parul[®]
Sevashram Hospital



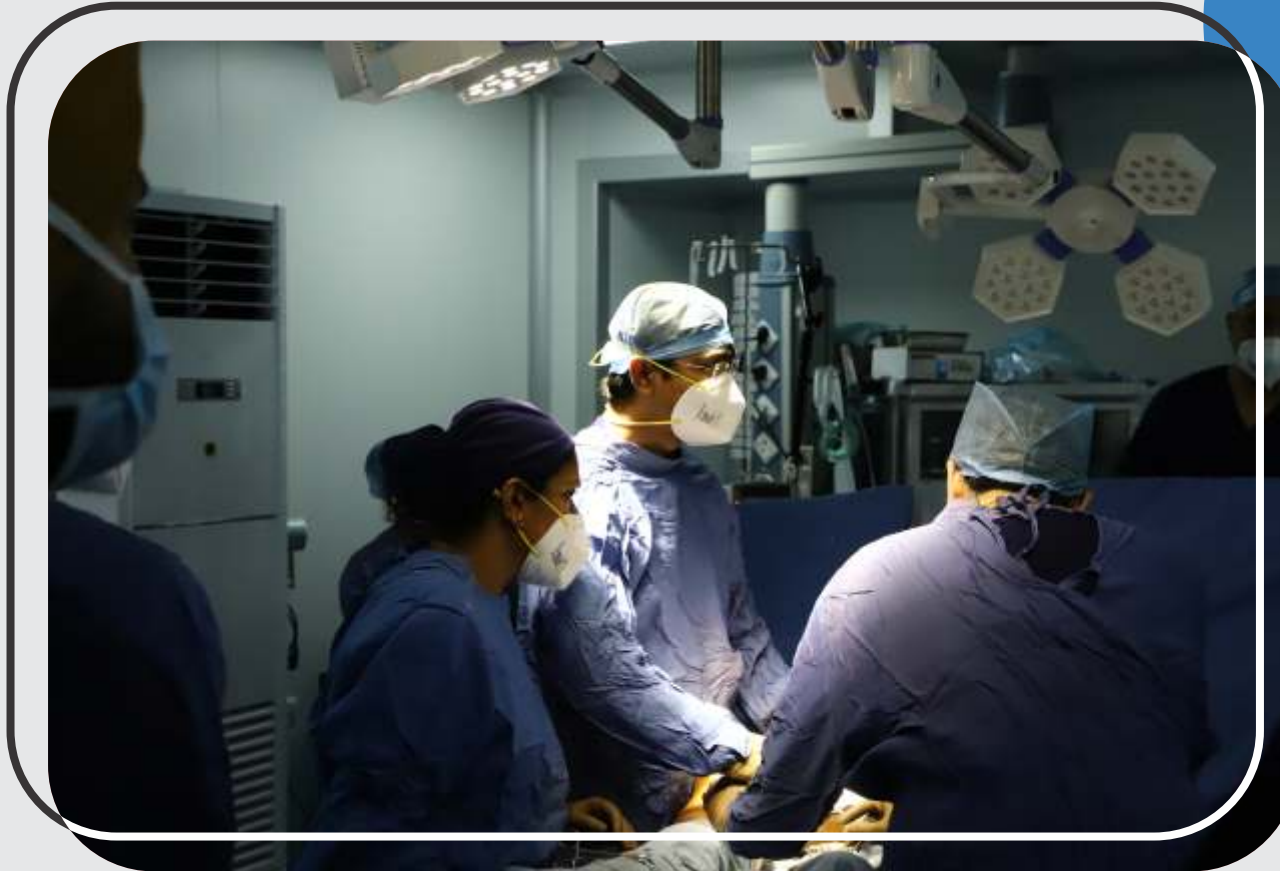Operating Surgeon :

Dr. Komal Patel, Dr. Akansha

Anaesthetist :

Dr. Krupa Patel, Dr. Hetal Parikh

Department of Obstetrics & Gynecology



Laprosopic Neovaginoplasty succesfully performed at Parul Sevashram Hospital for a 23 years old female having Primary Amenorrhea